

Mitral Valve Repair for Mitral Regurgitation in a patient with Systemic Lupus Erythematosus-A Case Report

Dr. Palanki Surya Satyagopal ¹, Dr. K. Sandeep Reddy¹, Dr. Satyapriyamohanty¹, Prof. R. V. Kumar¹,
Dr. T. Keerthi ², Prof. Liza Rajasekhar²

Department of CT Surgery¹, Department of Rheumatology²



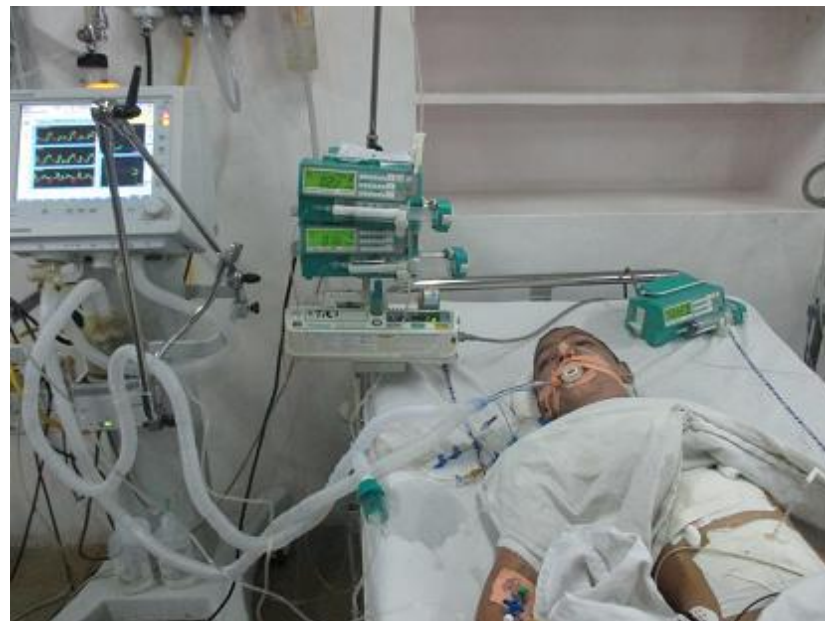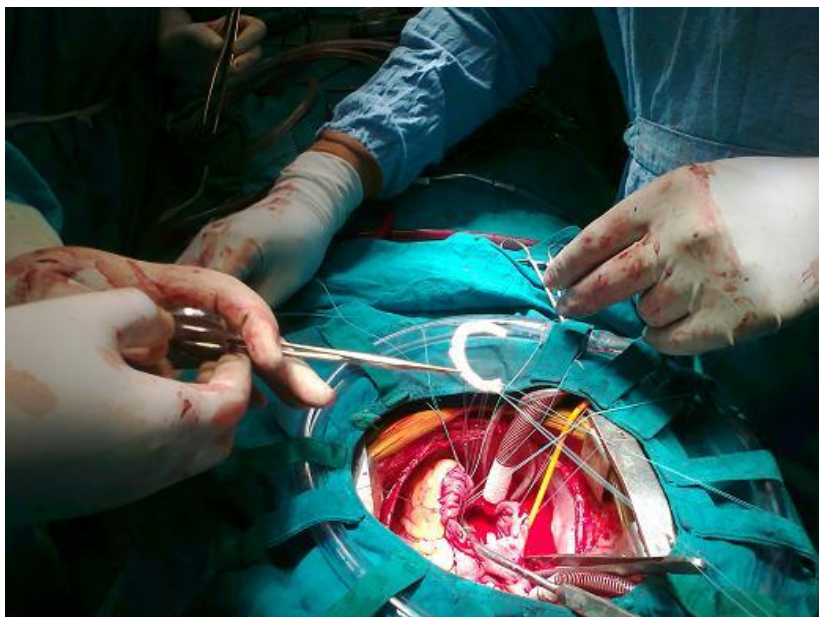
Introduction:

- Mitral valve regurgitation due to Systemic Lupus Erythematosus(SLE) is a rare cause of valvular heart disease, necessitating valve surgery.
- Currently, there are **only 47 case reports** in the world medical literature of mitral valve replacement or repair in patients who have lupus.
- **Immunologic insult** plays **a fundamental role in its pathogenesis.**
- Because of the lack of large systematic studies, **treatment options remain a challenge.**

Case report

- A 13 year old girl presented with exertional breathlessness and pedal oedema since 6 months.
- Patient was a known case of SLE for which she was being treated with oral steroids since 18 months.
- Patient had **no history of Rheumatic fever** in the past. Her physical exam revealed a blowing systolic murmur radiating to the left axilla.
- On evaluation found to have **Severe Mitral Regurgitation(MRJA:12cm²)**, Mild RV dysfunction and Normal LV function.
- **ANA and anti ds-DNA** were **positive**. **ASO titre** is **negative**. **CRP** is **positive**.
- **Anticardiolipin antibody (aCL)** is **negative** .**Renal parameters** were normal.

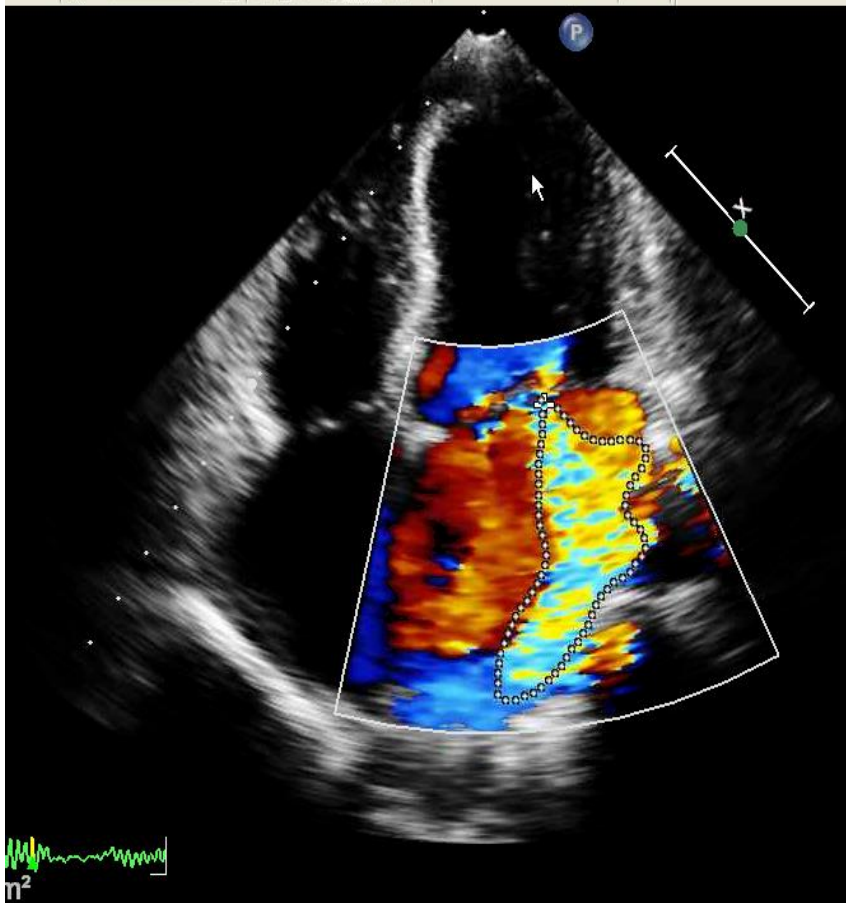
- Patient was taken up for elective surgery after initial medical stabilisation and control of SLE disease activity.
- Mitral valve repair done with **Teflon felt sized to 23 mm CE ring**, as leaflets were pliable and sub valvular apparatus was spared .



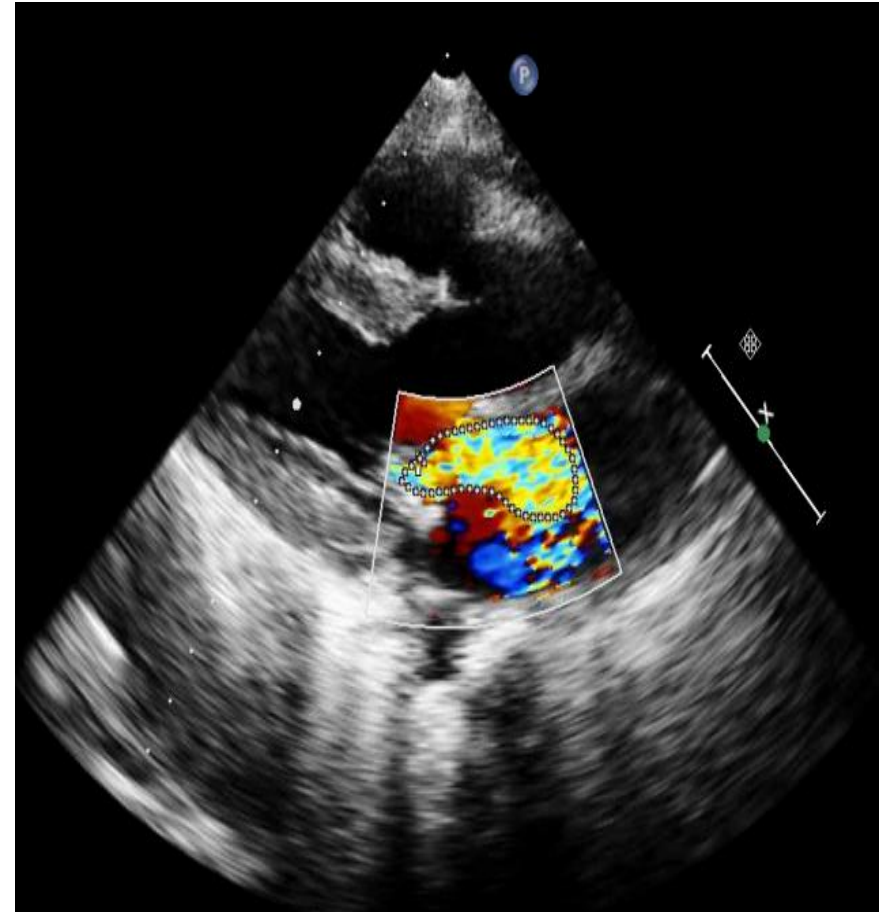
- Post operatively patient had acute kidney injury was managed with **Peritoneal dialysis and steroids**.
- Post operative Echocardiography revealed **mild MR (3 cm²)**. Patient was discharged on fifteenth post operative day.

Pre op echo

Post op echo



MRJA: 12cm²



MRJA: 3 cm²

Discussion

- According to the literature, the prevalence of cardiovascular involvement in patients with SLE has been estimated to be **more than 50%**[1, 4, 5, 12, 13].
- It was shown that **the left-sided heart valves are affected most commonly.**
- The **most frequently involved valve is the mitral valve followed by the aortic valve** and regurgitation represents the predominant abnormality [1, 2, 4, 6, 9].
- The **mitral valve involvement in patients with SLE** has been categorized as **leaflet thickening, vegetations (LS endocarditis), regurgitation, and valve stenosis** [1, 2, 5, 7–11, 12, 15].

- It is thought that **immunologic insults (infiltration of inflammatory cells and immune complex deposition)** play principal role.
- *Treatment of valvular manifestation* of SLE depends on the type and severity of involvement.
- Some investigators have suggested that the introduction of **corticosteroid** as the cornerstone of SLE treatment may **decrease the frequency of symptoms and disease activity** [4, 7, 13, 16].
- However, they can promote fibrosis, scarring (shortening of leaflet, chordae, and valve deformity), and thickening, resulting in additional damage and valve dysfunction [1, 4, 5, 7, 15]

- *Valve surgery may be required if severe symptomatic valvular dysfunction persists [5, 7].*
- There is **no definite consensus** about surgical procedure: **repair versus replacement and mechanical versus biologic valve** [5, 12, 13, 15].
- In current cardiac surgery, there is **no doubt about the superiority of mitral valve repair versus replacement** whenever possible for most cases of mitral regurgitation by different etiologies [5].

- MV repair is associated with better preservation of left ventricular function and fewer valve related complications [3].
- If SLE status has been fairly stable with medical management and intraoperative examination shows absence of severe structural damage (with only localized and limited abnormalities), if repair seems possible and practical, then mitral valve repair is the preferred surgical option [3, 5, 12, 13].
- *Valve replacement has been suggested when there is extensive fibrosis relating to papillary muscles. Subvalvular apparatus preservation should be done whenever possible.* [5]

- In the subject of mitral valve replacement, **prosthetic valve selection is highly individualized** based on **age, APS association**, and other conditions such as situations which need a prolonged anticoagulation use, like **atrial fibrillation** [3, 5, 12].
- Although successful placement of **biologic valve** has been reported, **massive thrombosis, leaflet perforation, valvulitis, and rapid mineralization** were described in this situation [5, 12, 13].
- **If renal involvement is prominent feature** in SLE patient, use of **mechanical valve provides better result** although the risk of thromboembolic events remains. [5, 12, 14].

Conclusion

- The experience with mitral valve surgery in SLE patients is limited.
- If there is localized abnormality in structure and function of mitral valve in relatively stable and controlled SLE patient, valve repair is a better choice.
- Although timely diagnosis is essential to prevent progression of valvular lesions, treatment remains a challenge because of the lack of large systematic studies.

References

- [1] J. Bourr'e-Tessier, T. Huynh, A. E. Clarke et al., "Features associated with cardiac abnormalities in systemic lupus erythematosus," *Lupus*, vol. 20, no. 14, pp. 1518–1525, 2011.
- [2] A. Amoroso, F. Cacciapaglia, S. De Castro et al., "The adjunctive role of antiphospholipid antibodies in systemic lupus erythematosus cardiac involvement," *Clinical and Experimental Rheumatology*, vol. 24, no. 3, pp. 287–294, 2006.
- [3] C. M. Vassileva, M. N. Swong, T. M. Boley, S. J. Markwell, and S. R. Hazelrigg, "Influence of systemic lupus erythematosus on procedure selection and outcomes of patients undergoing isolated mitral valve surgery," *Journal of Cardiac Surgery*, vol. 27, no. 1, pp. 29–33, 2012.
- [4] L. W. Lan, C. Tsai, and C. J. Hou, "The valvular involvement of lupus: congestive heart failure can be the presenting feature of systemic lupus erythematosus," *Acta Cardiologica Sinica*, vol. 21, no. 2, pp. 111–115, 2005.
- [5] W. Bouma, T. J. Klinkenberg, I. C. C. vanderHorst et al., "Mitral valve surgery for mitral regurgitation caused by Libman-Sacks endocarditis: a report of four cases and a systematic review of the literature," *Journal of Cardiothoracic Surgery*, vol. 5, no. 1, article 13, 2010.
- [6] C.-H. Lin, M.-L. Lee, and R.-B. Hsu, "Cardiac surgery in patients with systemic lupus erythematosus," *Interactive Cardiovascular and Thoracic Surgery*, vol. 4, no. 6, pp. 618–621, 2005.
- [7] E. Ferreira, P. M. Bettencourt, and L. M. Moura, "Valvular lesions in patients with systemic lupus erythematosus and antiphospholipid syndrome: An old disease but a persistent challenge," *Revista Portuguesa de Cardiologia*, vol. 31, no. 4, pp. 295–299, 2012.
- [8] G. Ruiz-Irastorza, M. Garmendia, I. Villar, M. Egurbide, and C. Aguirre, "Pulmonary hypertension in systemic lupus erythematosus: prevalence, predictors and diagnostic strategy," *Autoimmunity Reviews*, vol. 12, no. 3, pp. 410–415, 2013.

- [9] N. E. Doherty and R. J. Siegel, "Cardiovascular manifestations of systemic lupus erythematosus," *The American Heart Journal*, vol. 110, no. 6, pp. 1257–1265, 1985.
- [10] M. Hojnik, J. George, L. Ziporen, and Y. Shoenfeld, "Heart valve involvement (Libman-Sacks endocarditis) in the antiphospholipid syndrome," *Circulation*, vol. 93, no. 8, pp. 1579–1587, 1996.
- [11] I. Moyssakis, M. G. Tektonidou, V. A. Vasilliou, M. Samarkos, V. Votteas, and H.M. Moutsopoulos, "Libman-Sacks endocarditis in systemic lupus erythematosus: prevalence, associations, and evolution," *American Journal of Medicine*, vol. 120, no. 7, pp. 636–642, 2007.
- [12] J. P. Hakim, A. Mehta, A. C. Jain, and G. F. Murray, "Mitral valve replacement and repair: report of 5 patients with systemic lupus erythematosus," *Texas Heart Institute Journal*, vol. 28, no. 1, pp. 47–52, 2001.
- [13] H. Gorki, V. Malinovski, and R. D. L. Stanbridge, "The antiphospholipid syndrome and heart valve surgery," *European Journal of Cardio-Thoracic Surgery*, vol. 33, no. 2, pp. 168–181, 2008.
- [14] P. Perier, M. Jeserich, M. Vieth, K. Pohle, W. Hohenberger, and A. Diegeler, "Mitral valve reconstruction in a patient with Libman-Sacks endocarditis: a case report," *The Journal of Heart Valve Disease*, vol. 20, no. 1, pp. 103–106, 2011.
- [15] J. Fernández-Dueñas, A. López-Granados, D. Mesa-Rubio, J. Ariza-Cañete, M. Gallo-Marín, and M. Concha-Ruiz, "Severe mitral regurgitation in Libman-Sacks endocarditis. Conservative surgery," *Revista Española de Cardiología*, vol. 58, no. 9, pp. 1118–1120, 2005.
- [16] J. A. Kohler Sr. and A. R. Ellis, "Libman-Sacks endocarditis in pediatric patient with systemic lupus erythematosus," *Pediatric Cardiology*, vol. 33, no. 8, pp. 1466–1468, 2012.

Thank you!